

Original article:

Variations in the Arterial Supply of Abdominal Viscera and Branches of Lumbar Plexus in a Single Cadaver

¹Dr. Biswapriya Sinha , ²Dr. Parijat Mukherjee , ³Dr. Arunima Nag (Ray) , ⁴Dr. Rajarshi Dutta ,
⁵Dr. Chiranjit Samanta , ⁶Prof. (Dr.) Sudeshna Majumdar

¹ Demonstrator, Department of Anatomy , North Bengal Medical College, Sushrutanagar, Darjeeling – 734012. West Bengal, India.

² Junior Resident, Department of Anatomy, North Bengal Medical College, Sushrutanagar, Darjeeling – 734012. West Bengal, India.

³ Junior Resident , Department of Anatomy, North Bengal Medical College, Sushrutanagar, Darjeeling – 734012. West Bengal, India.

⁴ Contractual medical officer (Specialist), Department of Anatomy, North Bengal Medical College, Sushrutanagar, Darjeeling – 734012. West Bengal, India.

⁵ Contractual medical officer (Specialist) , Department of Anatomy, North Bengal Medical College, Sushrutanagar, Darjeeling – 734012. West Bengal, India.

⁶ Professor and Head of the Department of Anatomy, North Bengal Medical College, Sushrutanagar, Darjeeling – 734012. West Bengal, India.

Corresponding author: Prof. (Dr.) Sudeshna Majumdar

ABSTRACT

In February, 2017, while doing the routine dissection inside the abdomen of a 70 year old male cadaver, in the department of anatomy, North Bengal Medical College, West Bengal, several variations were found in the arterial supply of the abdominal viscera and branches of lumbar plexus. There were double right colic artery (emerging from the superior mesenteric artery). An accessory renal artery reached the lower pole of the right kidney after emerging from the abdominal aorta from its right side and there were double renal veins in the same kidney. Moreover, the genitofemoral nerve on the left side divided into genital and femoral branches in the upper one-third of the psoas major muscle and on the right side, common trunk (the ventral ramus of L1) emerged through the psoas major muscle to bifurcate into the iliohypogastric and ilioinguinal nerves.

This case report will enhance our knowledge in gross anatomy and will be of help for surgical , radiological or other clinical interventions in abdomen .

Key Words: Right colic artery, Accessory renal artery, renal veins lumbar plexus, iliohypogastric and ilioinguinal nerves, genitofemoral nerve , renal veins

INTRODUCTION

The right colic artery is a small vessel that is highly variable in its anatomy. It may arise as a separate branch from the right side of the superior mesenteric artery. Most commonly it arises as a common trunk from the middle colic artery and passes towards the ascending colon, deep to the parietal peritoneum and anterior to the gonadal vessels, right ureter and psoas major. Near the colon, it divides into a descending branch, which anastomoses with the ilioocolic artery and an ascending branch, that anastomoses with the right branch of the middle colic artery. These form the marginal artery in the area of the hepatic flexure from which vessels are distributed to the upper third of the ascending colon and right side of the transverse colon. Separate right colic artery, arising from the superior mesenteric artery passes towards the ascending colon in 35% cases [1].

One or two accessory renal arteries are present in 30% individuals [2]. They frequently arise, (specially on the left side) usually from the aorta, above or below the main artery, enter the kidney above or below the renal hilum; if below, the vessel passes anterior to the ureter and on the right side, usually anterior to the inferior vena cava [1].

Accessory renal arteries are common in 20–30% of individuals, usually arising from the aorta above or below the main renal artery. The variation in the number of arteries is because of persistence of lateral splanchnic arteries or due to the persistence of blood supply from lower level than normal. [2,3].

The left gastric artery is the smallest branch of the celiac trunk. It ascends to the left of the midline, crosses the left crus of the diaphragm beneath the peritoneum of the upper posterior wall of the lesser sac. Here, it lies adjacent to the left inferior phrenic artery and medial or anterior to the left supra-renal

gland [4]. In its course along the lesser curvature it gives off multiple branches that run onto the anterior and posterior surfaces of the stomach, after which it anastomoses with the right gastric artery [4].

The lumbar plexus lies within the substance of the posterior part of the psoas major muscle, anterior to the transverse processes of lumbar vertebrae. It is formed by the first three and most of the fourth lumbar ventral rami and a contribution from the 12th thoracic ventral ramus. The first lumbar ventral ramus, joined by a branch from the 12th thoracic ventral ramus bifurcates and the upper and large part divides again into the iliohypogastric and the ilioinguinal nerves. The smaller lower part unites with a branch from the second lumbar ventral ramus to form the genitofemoral nerve. [1]

The iliohypogastric nerve originates from the L1 ventral ramus. It emerges from the upper lateral border of psoas major, crosses obliquely behind the lower renal pole and in front of the quadratus lumborum [1].

The Ilioinguinal Nerve originates from the L1 ventral ramus. It is usually smaller than the iliohypogastric nerve arises with it from the first lumbar ventral ramus, to emerge from the lateral border of psoas major. It passes obliquely across the quadratus lumborum and upper part of the iliacus and enters the quadratus lumborum near the anterior end of the iliac crest, where it sometimes connects with the iliohypogastric nerve [1].

The Genitofemoral Nerve: This is a branch of the lumbar plexus (root value - L1 & L2 ventral rami) and is formed within the substance of the psoas major. It descends obliquely forwards through the muscle to emerge on its abdominal surface near the medial border, opposite the third and fourth lumbar vertebrae. It runs beneath the peritoneum and above

the inguinal ligament and gives the genital and femoral branches. It often divides close to its origin and the branches emerge separately from the psoas major [1].

AIMS AND OBJECTIVES

The variations in the vascular supply of the abdominal viscera and variations among the branches of the lumbar plexus and other features were studied in this case report to enhance our knowledge in gross and clinical Anatomy.

MATERIALS AND METHODS

During the routine dissection for undergraduate students in the Department of Anatomy, North Bengal Medical College, West Bengal, in the month of February, 2017, variations were found in the abdomen of a 70 year old embalmed male cadaver in the blood supply of the abdominal viscera and among the branches of the lumbar plexus.

Dissection was done minutely in the abdomen, structures were observed in details and relevant photographs were taken.

OBSERVATIONS

The right colic artery arose from the superior mesenteric artery and passed towards the ascending colon horizontally. Below and parallel to that a

separate right colic artery also arose from the superior mesenteric artery and followed the same direction. These two arteries formed a part of the marginal artery (**Figures 1 & 2**).

There was an accessory renal artery, arising from the right side of the abdominal aorta, passed obliquely (upwards and laterally) to the right side to reach the lower pole of the right kidney. Moreover, in the hilum of the right kidney **two renal veins** emerged to drain into the inferior vena cava after joining with each other (**Figure – 3**).

Along the lesser curvature of stomach there were intricate arterial branches of the left and right gastric arteries (**Figure – 4**).

The iliohypogastric and the ilioinguinal nerves on the right side arose from a common trunk (ventral ramus of L1) of the lumbar plexus. The common nerve emerged from the lateral border of the right psoas major muscle and then divided into iliohypogastric and ilioinguinal nerves (**Figure – 5**).

On the left side the division of the **genitofemoral nerve** into genital and femoral branches took place in the upper one- third of the psoas major muscle after the main trunk pierced the anterior surface of the muscle (**Figure – 6**).

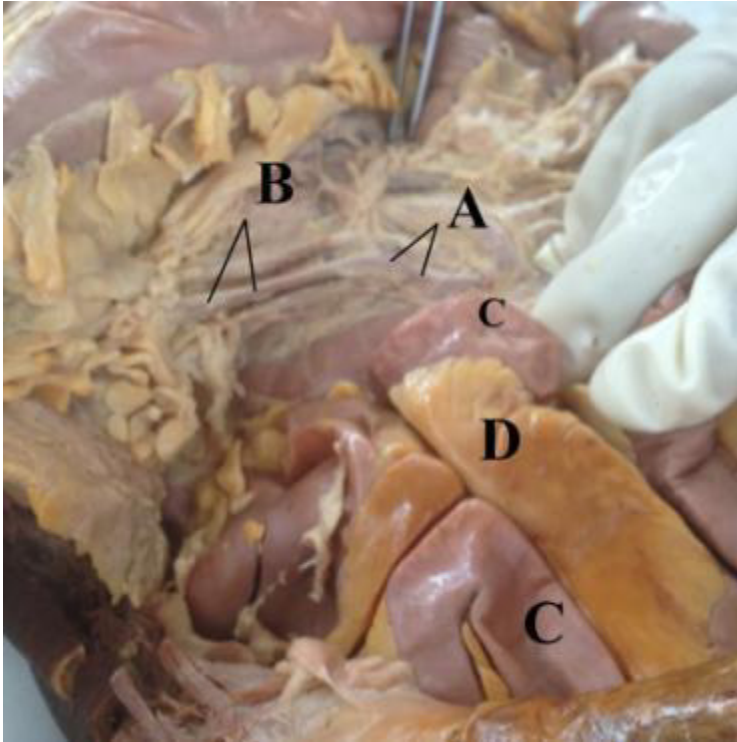


Figure: 1 – Two right colic arteries (B), arising from the superior mesenteric artery (A). Small intestine (C) with mesentery (D) are visible beside .

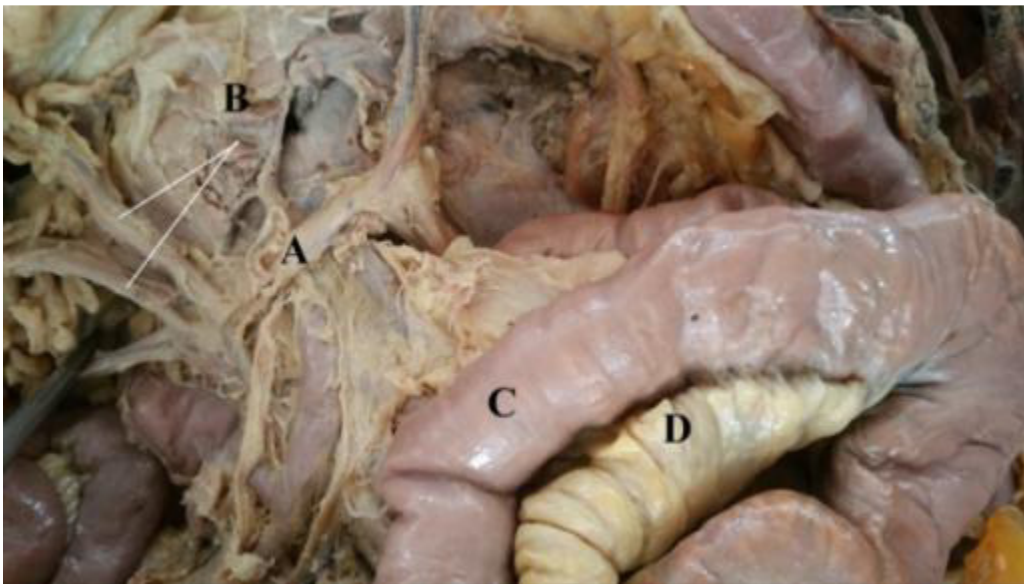


Figure: 2 - Two right colic arteries (B), arose from the superior mesenteric artery (A), Small intestine (C) with mesentery (D) are visible beside .

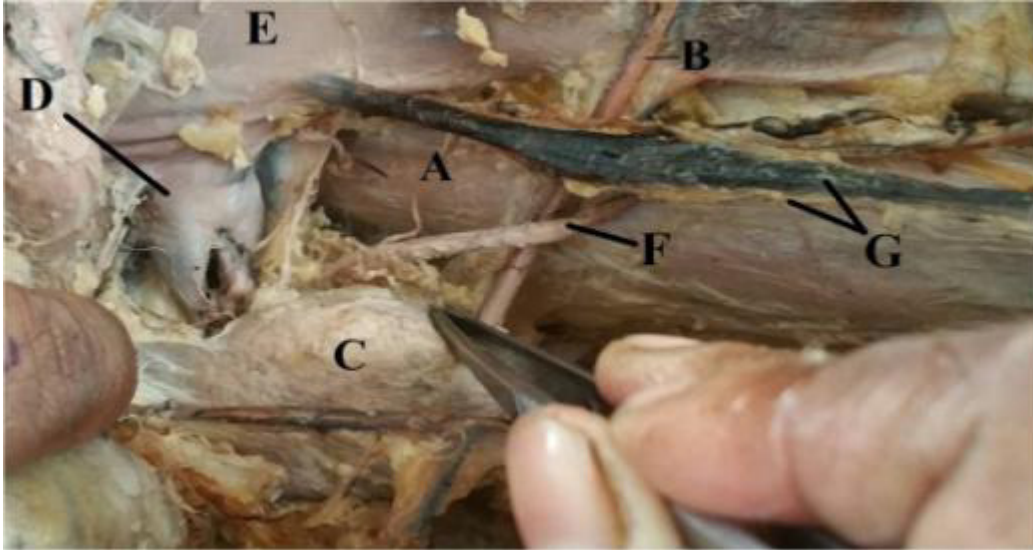


Figure: 3 – One Accessory renal artery (B) reached the lower pole of the right kidney (C) passing over the right psoas major muscle (A). Two renal veins emerged (D) in the hilum to drain into the inferior vena cava (E) after joining with each other. The right ureter (F) and the right gonadal vessels (G) are also visible .

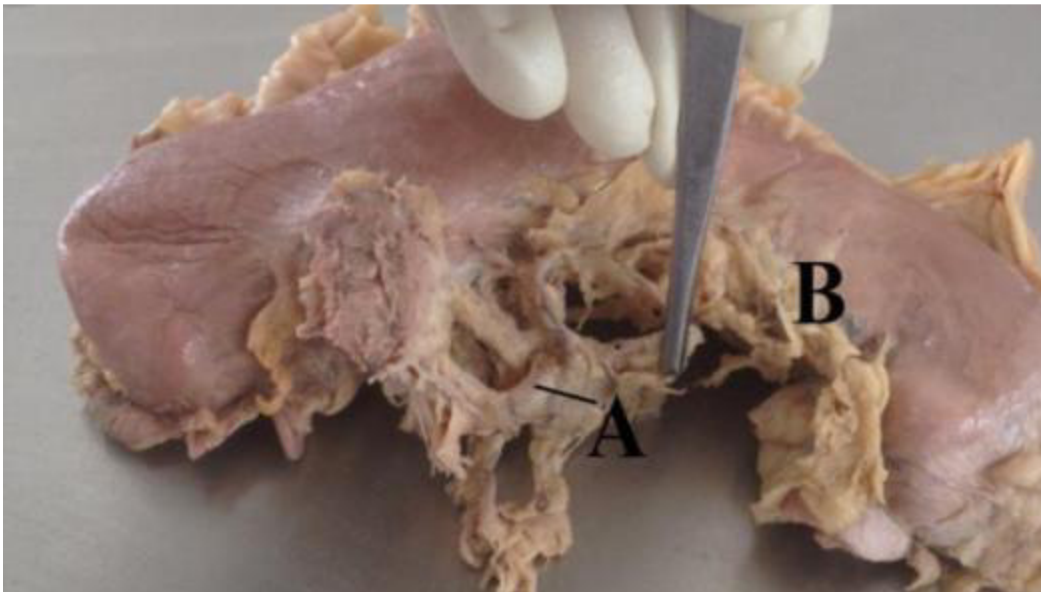


Figure – 4; arterial branches of the left and right gastric arteries (A) along the lesser curvature of stomach (B).

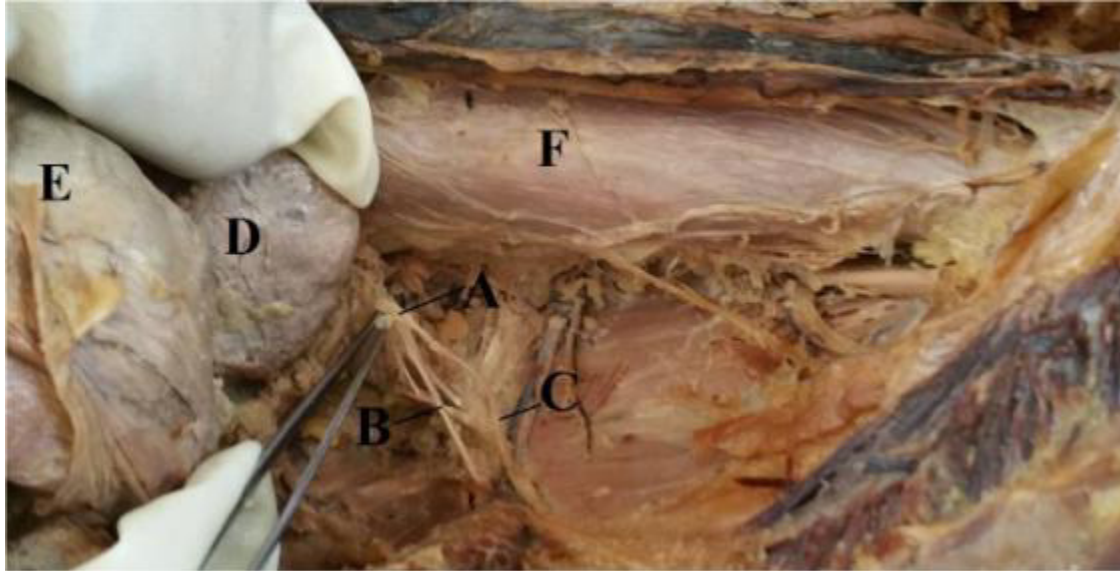


Figure – 5 ; The common trunk of ventral ramus of L1 (A) emerged from the psoas major muscle (F) and bifurcated into iliohypogastric (B) and ilioinguinal (C) nerves on the right side. The overlying right kidney and transverse colon are also visible.

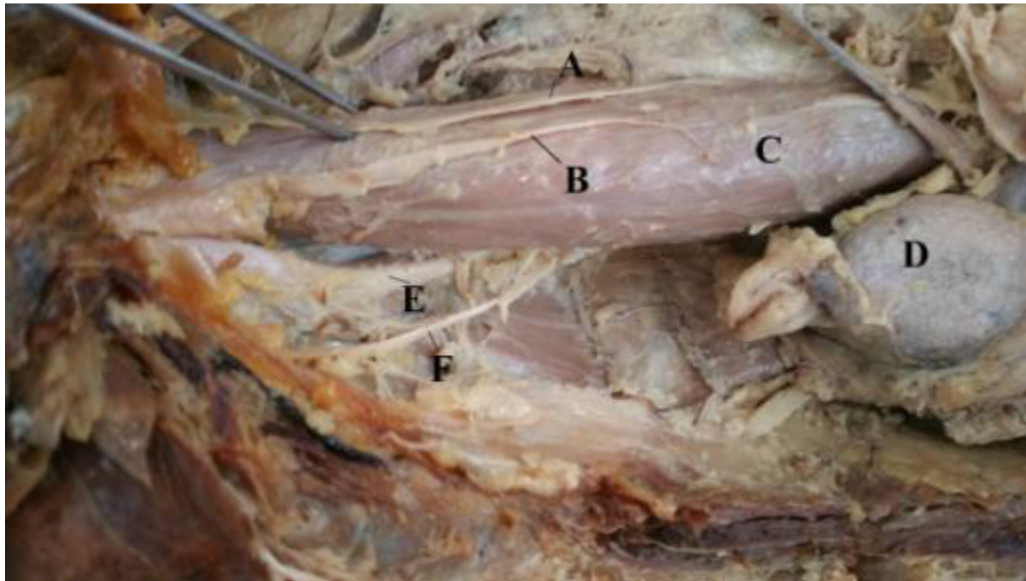


Figure – 6; The left genitofemoral nerve bifurcated into genital (A) and femoral (B) branches in the upper part of the psoas major muscle (C) . The overlying right kidney (D) and transverse (E) are also visible

DISCUSSION:

In 35% cases a separate right colic artery, arises from the superior mesenteric artery and passes towards the ascending colon [1].

Embryologically, renal and gonadal arteries are the lateral splanchnic branches of the dorsal aortae. These branches supply the mesonephros,

metanephros, gonads (testis and ovary) and the suprarenal gland. The renal artery branches are the most cranial in position.

Multiple renal arteries occurred bilaterally in 10.2% of donors and unilaterally in 20.8%, a total incidence of 31%. There was a higher incidence of vascular-related complications following transplantation of

kidneys with multiple renal arteries [2,3]. Knowledge of the variations in the renal arteries is important for urologists, radiologists and surgeons in general [3].

Majumdar et al., in 2013, described a case with one accessory renal artery emerged from the left side of the abdominal aorta, passed laterally, above the main left renal artery and reached the upper pole of the left kidney to enter the parenchyma of the organ.[5]. In 2013, Majumdar et al, stated a case with bilateral double renal veins (on the right side two renal veins emerged from the hilum of the right kidney to drain into the inferior vena cava [IVC] separately and on the left side, two renal veins emerged from hilum of the left kidney, joined with each other to drain into IVC as a single vein) [6] .

In an extensive study, Pick and Anson found that 40.5% of all kidneys examined, had more than two vessels, that was, more than a single artery and a single vein [7]. For most part of the body, variations or anomalies of veins are far more frequent than those of arteries, but this is not true of the vascular pedicle of kidney. Supernumerary veins are present in 14.4% and supernumerary arteries are present in 32.25% of the kidneys [7].

This vascular variation shows a major significance in renal surgery, in partial or total nephrectomy and in renal transplant [8] . The renal hilum should be examined properly prior to any surgical procedure in this region by radiographic examination [9].

The prevalence of the anatomical variations in the individual nerves of lumbar plexus ranges from 8.8 to 47.1% with a mean prevalence of 20.1%.

REFERENCES

1. Standring S, Borely NR, Healy JC, Collins P, Brown JL, Wigley C, Khan N, Moore LA, Lowe D (editors). In: Gray's Anatomy, The Anatomical Basis of Clinical Practice. Posterior abdominal wall and

Anatomical variations included absence of iliohypogastric nerve, an early range of the genitofemoral nerve into genital and femoral branches, etc. [10].

Typically, the genitofemoral nerve bifurcates into its terminal genital and femoral branches midway along the anterior surface of the psoas major. In a study conducted by Anloague et al, it was found that the most common variation of the genitofemoral nerve occurred in 9 of 34 lumbar plexuses (26.5%) and included a split of the genitofemoral nerve into the genital and femoral branches within the substance of the psoas major muscle with fibers of the psoas major passing between these branches. Seven variant genitofemoral nerves (20.6%) had this bifurcation occurring at the upper rather than mid portion of the anterior surface of the psoas [10]. In the present case, the genitofemoral nerve bifurcated in the upper portion of the psoas major muscle on the left side.

CONCLUSION

This case will be of help for the vascular surgery, renal surgery and other surgical approaches in abdomen along with increasing our knowledge in gross Anatomy.

ACKNOWLEDGEMENT

We are grateful to all the members of the Department of Anatomy, North Bengal Medical College, Sushrutanagar, West Bengal, for their kind cooperation to complete this study.

- retroperitoneum; Large Intestine; Kidney and Ureter. 40th Edition. Spain, Philadelphia; Churchill Livingstone Elsevier. 2011:1078, 1080, 1144, 1231.
2. Williams PL, Bannister HL, Martin MB, Collins P, Dyson M, Dussek EJ, Ferguson W, Glabella JM (editors). Gray's Anatomy. 38th edition . Churchill and Livingstone, London and other cities. 1995; 316-318 and 1557- 1558.
 3. Mir NS1, Ul Hassan A, Rangrez R, Hamid S, Sabia, Tabish SA, Iqbal, Suhaila, Masarat, Rasool Z. Bilateral duplication of renal vessels: anatomical, medical and surgical perspective. *Int J Health Sci (Qassim)*. 2008; 2(2): 179–185.
 4. Standring S, Stringer MD, Barr H, Almond L (editors). In: Gray's Anatomy, The Anatomical Basis of Clinical Practice. Abdominal Oesophagus and Stomach. 41st Edition. Elsevier. 2015; p - 1116.
 5. Majumdar S, Bhattacharya K, Kundu P, Mandal S, Roy H. Variations in the renal and testicular arteries. *Indian Journal of Basic & Applied Medical Research*. 2013; 2(6): 502-506.
 6. Majumdar S, Mazumdar S, Ghoshal AK, Roy H. A case of bilateral double renal veins. *International Journal of Anatomical Variations (IJAV)* ; 2013; 6: 61–6.
 7. Pick JW, Anson BJ. The renal vascular pedicle. An anatomical study of 430 body halves. *J Urol*. 1940; 44: 411–434.
 8. Dhar P, Lal K. Main and accessory renal arteries--a morphological study. *Ital J Anat Embryol*. 2005; 110: 101–110.
 9. Soni S, Wadhwa A. Multiple Variations in the paired arteries of abdominal aorta – clinical implications. *J Clin Diagn Res*. 2010; 4: 2622–2625.
 10. Anloague PA, Huijbregts P. Anatomical Variations of the Lumbar Plexus: A Descriptive Anatomy Study with Proposed Clinical Implications. *J Man Manip Ther*. 2009; 17(4): e107–e114. PMID.